

## Case Report

## Open Access

## Posterior Spinal Artery Territory Syndrome Following Treatment of a Basilar Artery Aneurysm with a Pipeline Embolization Device: A Case Report

Ahmad S Ali\*, Sudheesh Ramachandran, Volodymyr Vulkanov, Priyank Khandelwal and Machteld Hillen

Faculty/Staff within Rutgers New Jersey Medical School, Neurology Department, USA

### ABSTRACT

Posterior spinal artery infarcts are exceedingly rare due to high level of collateral circulation in the spinal cord. Additionally thromboembolic phenomenon is a potential complication during aneurysm stenting via digital subtraction angiography (DSA). Hereby, we report a case of posterior spinal artery syndrome following cerebral angiography and endovascular basilar artery pipeline embolization (PED) for basilar artery aneurysm. Our goal is to outline successful diagnosis and management of this rare event. Our patient is a 59-year-old female with a basilar artery aneurysm. Following treatment of an intracranial proximal basilar artery aneurysm with a Pipeline Embolization Device, she presented as bilateral dorsal cord syndrome. On exam, she had isolated findings of loss of vibration and joint position sense in her feet and ankles, accompanied by the presence of T2 hyperintensity in the nuclei gracilis at C2-3 on MRI cervical spine is consistent with arterial thromboembolism during her procedure. Although posterior spinal artery infarct is infrequently reported in the literature, it is a potential complication of posterior fossa endovascular intervention. The presence of sensory symptoms following a basilar artery procedure should alert physicians to involvement of the dorsal columns of the upper cervical cord due to PSA ischemia.

### \*Corresponding author

Ahmad S Ali, Faculty/Staff within Rutgers New Jersey Medical School, Neurology Department, USA.

**Received:** November 12, 2024; **Accepted:** November 16, 2024; **Published:** November 25, 2024

### Introduction

Spinal cord infarction is a rare clinical entity compared to cerebral strokes, accounting for 0.3 to 1% of all strokes. It is caused by acute disruption of blood supply to the spinal cord resulting in ischemia, infarction and acute spinal cord dysfunction. They are usually characterized by catastrophic neurological deficits owing to high concentration of neuronal matter per unit area [1,2].

The spinal cord is largely perfused by the anterior spinal artery and 2 posterior spinal arteries (PSA), which are further supplemented by numerous radicular arteries. Most people have 4 to 10 anterior radicular arteries and 10 to 23 posterior radicular arteries [3]. Owing to the extensive anastomotic network, PSA strokes are exceedingly rare. The etiology of PSA strokes is not entirely clear, however most authors agree that they are usually spontaneous [4].

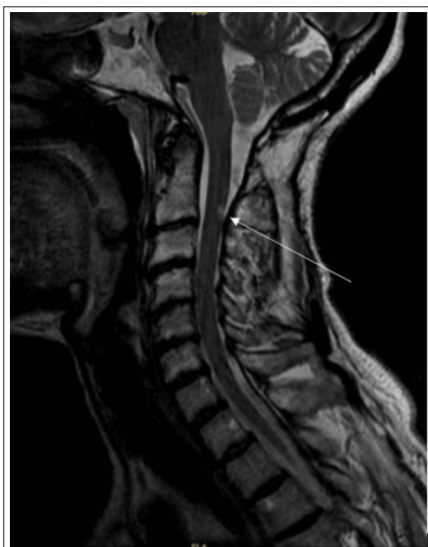Spinal cord strokes are known to occur following extracranial surgical or endovascular interventions, such as repair of aortic aneurysm/dissection and vertebral artery dissection [2]. We present a rare case of PSA stroke following pipeline embolization (PED) and flow diverter placement for proximal basilar artery aneurysm presenting as bilateral dorsal cord syndrome.

### Case Presentation

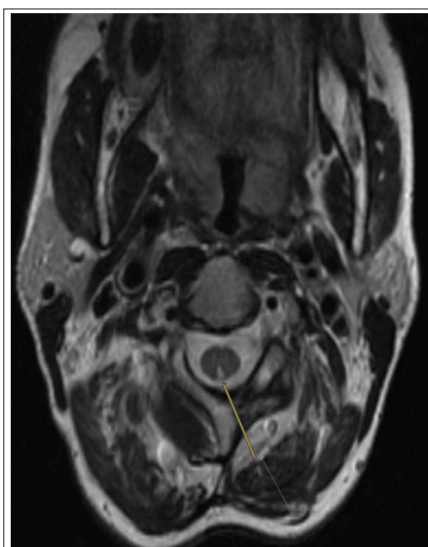
A 59-year-old woman with a history of multiple intracranial aneurysms, previously managed via endovascular embolization and clipping, presented with numbness and heaviness that started after she underwent successful DSA for pipeline embolization device placement for a newly diagnosed unruptured 2.48mm x

2.22 mm proximal basilar artery aneurysm, adjacent to origin of the right anterior inferior cerebellar artery. She tolerated the procedure well without immediate complications, however after her sedation wore off, she started to experience sensory symptoms described as numbness and tingling, from her mid-abdomen radiating to both lower extremities, in addition to heaviness of both legs. She denied any symptoms in her upper extremities, focal motor weakness, urinary or bowel incontinence, but endorsed gait instability, especially when trying to get up from a chair. Neurologic examination showed intact muscle strength, coordination, light touch and pinprick sensation with loss of vibratory and joint position in both feet and ankles up to her mid-shin. Her Romberg test was positive, and her gait was slightly wide based.

She was diagnosed with sensory ataxia. Blood work showed normal HbA1C, vitamin B12, folate and TSH; negative RPR and she had no history of alcohol use. MRI of the cervical spine without contrast showed a small focus of increased T2/STIR signal intensity in the dorsal midline at the level of C2-3, involving bilateral nuclei gracilis (Figure 1 and Figure 2). There was no evidence of disc herniation or central canal stenosis. MRI brain without contrast was obtained to rule out basilar artery perforator stroke given procedure's proximity to basilar perforators, which did not show a stroke. She was diagnosed with a PSA stroke given the rapid onset and nature of her symptoms. She was started on gabapentin, which was switched to pregabalin due to lack of response to gabapentin, and she received physical and occupational therapies with improvement in her function.



**Figure 1:** MRI of the Cervical Spine Without Contrast Showing a Small Focus of Increased T2/STIR Signal Intensity in the Dorsal Midline at the Level of C2-3, Sagittal



**Figure 2:** MRI of the Cervical Spine Without Contrast Showing a Small Focus of Increased T2/STIR Signal Intensity in the Dorsal Midline at the Level of C2-3, Axial

## Discussion

Spinal cord infarction is estimated to account for 1% to 2% of ischemic strokes. Perfusion of the anterior two-thirds of the spinal cord occurs via the anterior spinal artery, and the posterior one-third region of the spinal cord receives its supply by the two PSAs. Among these, PSA infarction is significantly less frequent compared to anterior spinal cord infarction. The lower incidence of PSA infarcts can be attributed to the dual posterior arterial blood supply, which includes numerous anastomoses [1]. The two PSAs typically originate from either the vertebral arteries or, more commonly, the posterior inferior cerebellar arteries. These arteries descend along the posterior surface of the spinal cord, following the posterolateral sulcus. They are often found to be discontinuous, and in some cases, one artery may provide collateral supply to the opposite side. PSAs supply the posterior columns, posterior dorsal horns, and portions of the corticospinal and spinothalamic tracts. PSA infarction produces loss of proprioception and vibratory sense below the level of the injury. Weakness has been described but is typically mild and transient. Unilateral involvement is more

common, but bilateral presentations have been described [3,5].

Basilar artery aneurysms make up approximately 3% to 5% of intracranial aneurysms. Their critical location necessitates careful evaluation. The most dreaded complication of cerebral aneurysms is rupture and subsequent subarachnoid hemorrhage which can be fatal. Current therapeutic options are limited to invasive therapies, namely microsurgical clipping and endovascular treatment, both of which carry a risk of procedural morbidity. Endovascular treatment is considered first-line for basilar artery aneurysms given the deep anatomy of basilar artery trunk [6,7]. While endovascular approach for basilar artery aneurysms is generally considered a safe and effective treatment, like any medical procedure, it carries potential risks and complications. One possible complication of endovascular basilar artery stent placement is arterial thromboembolism [8-11]. It is important to identify risk factors associated with procedural thromboembolism, including procedure-related factors, such as procedure time, extent of procedure manipulations, operator experience, and patient factors such as patient age, aneurysm size and location, presence of subarachnoid hemorrhage which induces vasospasm, smoking. Furthermore, during the procedure, intimal injury to the arterial vessel, potentially caused by microcatheter displacement or stent insertion, can trigger the release of procoagulant tissue factors, leading to the formation of a platelet-rich thrombus. To minimize the risk of thromboembolism during DSA, it is essential to implement careful management and preventive strategies. These include intraprocedural anticoagulation, premedication with antiplatelet agents, ensuring adequate hemostasis, and employing controlled catheter techniques [6,11].

According to Chen F et al, 28 cases with PSA syndromes were identified in 22 articles, 12 cases due to atherosclerosis, 7 cases due to artery dissection and 3 cases of iatrogenic etiology [12]. To our knowledge, vertebral artery dissection and atherosclerosis were by far the most common etiology identified in reported cases of PSA syndromes [14,15]. We present a rare case of PSA stroke following treatment of a proximal basilar artery aneurysm with a PED, presenting as bilateral dorsal cord syndrome. We propose that our patient suffered an arterial thromboembolism of the PSA during treatment of her basilar artery aneurysm with PED, leading to acute onset of numbness and tingling below the waist, with loss of vibration sensation and joint position sensation in her feet and ankles, accompanied by the presence of T2 hyperintensity in the nuclei gracilis at C2-3 on MRI cervical spine is consistent with arterial thromboembolism during her procedure.

## Conclusions

To our knowledge, this is the first description of a patient with a stroke localized to nucleus gracilis following intracranial endovascular PED of a basilar artery aneurysm. The presence of sensory symptoms after a basilar artery procedure should alert physicians to involvement of the dorsal columns of the upper cervical cord due to PSA ischemia.

## References

1. Kramer CL (2018) Vascular disorders of the spinal cord. *CONTINUUM: Lifelong Learning in Neurology* 24: 407-426.
2. Rubin MN, Rabinstein AA (2013) Vascular diseases of the spinal cord. *Neurologic clinics* 31: 153-181.
3. Rojas S, Ortega M, Rodrí Guez Baeza A (2018) Variable anatomic configuration of the posterior spinal arteries in humans. *Clinical Anatomy* 31: 1137-1143.
4. Martirosyan NL, Feuerstein JS, Theodore N, Daniel D Cavalcanti, Robert F Spetzler, et al. (2011) Blood supply

- and vascular reactivity of the spinal cord under normal and pathological conditions: A review. *Journal of Neurosurgery Spine* 15: 238-251.
5. Matsubayashi J, Tsuchiya K, Shimizu S, Kitagawa N, Wakabayashi Y, et al. (2013) Posterior spinal artery syndrome showing marked swelling of the spinal cord: a clinico-pathological study. *The Journal of Spinal Cord Medicine* 36: 31-35.
  6. Kocur D, Paździora P, Przybyłko N, Kukier W, Baron J, et al. (2019) Thromboembolism during coiling of intracranial aneurysms: predictors and clinical outcome. *Videosurgery and Other Miniinvasive Techniques* 15: 319-328.
  7. Ihn YK, Shin SH, Baik SK, In Sup Choi (2018) Complications of endovascular treatment for intracranial aneurysms: management and prevention. *Interventional Neuroradiology* 24: 237-245.
  8. Winkler EA, Lee A, Yue JK, Kunal P Raygor, W Caleb Rutledge, et al. (2021) Endovascular embolization versus surgical clipping in a single surgeon series of basilar artery aneurysms: a complementary approach in the endovascular era. *Acta Neurochirurgica* 163: 1527-1540.
  9. Keng Siang Lee, John J Y Zhang, Vincent Nguyen, Julian Han, Jeremiah N Johnson, et al. (2022) The evolution of intracranial aneurysm treatment techniques and future directions. *Neurosurgical Review* 45: 1-25.
  10. Nam HH, Jang DK, Cho BR (2022) Complications and risk factors after digital subtraction angiography: 1-year single-center study. *Journal of Cerebrovascular and Endovascular Neurosurgery* 24: 335-340.
  11. Sakurai T, Wakida K, Nishida H (2016) Cervical posterior spinal artery syndrome: a case report and literature review. *Journal of Stroke and Cerebrovascular Diseases* 1: 1552-1556.
  12. Futao Chen, Xuemeng Liu, Tiantian Qiu, Chunxue Jia, Min Liu, et al. (2020) Cervical posterior spinal artery syndrome caused by spontaneous vertebral artery dissection: two case reports and literature review. *Journal of Stroke and Cerebrovascular Diseases* 29: 104601.
  13. Junya Tatezaki, Kana Takase, Kagemichi Nagao, Yasunori Takemoto, Yasuhiko Mochimatsu (2021) Spinal Cord Infarction after Mechanical Thrombectomy for Acute Basilar Artery Occlusion: A Case Report and Review of the Literature. *Journal of Neuroendovascular Therapy* 15: 540-545.
  14. Kiyoko Murata, Ken Ikeda, Mitsuaki Muto, Takehisa Hirayama, Osamu Kano, et al. (2012) A case of posterior spinal artery syndrome in the cervical cord: a review of the clinicoradiological literature. *Internal Medicine* 51: 803-807.
  15. Wataro Tsuruta, Tetsuya Yamamoto, Go Ikeda, Masayuki Sato, Yoshiro Ito, et al. (2018) Spinal cord infarction in the region of the posterior spinal artery after embolization for vertebral artery dissection. *Operative Neurosurgery* 1: 701-710.