

Short Commentary

Open Access

Nasal Reconstruction in Darker Skin: Is the Subunit Principle Valid?!

Badr M I Abdulrauf MD FRCSC

Section of Plastic Reconstructive Surgery, Department of Surgery
King Faisal Specialist Hospital and Research Center Jeddah Saudi Arabia

ABSTRACT

The Subunit principle of Aesthetic Nasal Reconstruction is well known among Reconstructive surgeons and it is considered to be the excellence of care. It advocates to reconstruct a nasal defect as per the specific subunit, placing the suture line at a border of one subunit and its adjacent within the nasal surface.

Individuals with skin types III to V are prone to hyperpigmentation, hypertrophic scars, keloids and obvious suture marks. Applying the Subunit principle in these darker complexion patients would not be sufficient. In fact, it would result in a scarred nose with a patch. With our frequent experience in such cases, it was very important to revisit the mentioned principle.

In darker complexion individuals requiring significant part of their nose to be reconstructed, a consideration should be given to entire nasal unit reconstruction. This would allow placing the seams at junction with adjacent regions (cheek, lip) rather than within the nose and much acceptable aesthetic outcome.

*Corresponding author

Badr M I Abdulrauf MD FRCSC, Program Director, Plastic Surgery, KFSH&RC (General Organization), PO Box 40047 Jeddah 21499 KSA.
E-mail: badrplastics@gmail.com

Received: June 23, 2020; **Accepted:** June 27, 2020; **Published:** July 02, 2020

Keywords: Facial, Nasal, Units, Subunits Aesthetic, Reconstruction, Skin, Type, Dark, Complexion

The expression Aesthetic reconstruction refers to restoration post disease or trauma process to near normal appearance. It is Gonzalez - Ulloa who first described "Ridges and Valleys" or slightly convex or concave surfaces on the face. They explained these terrains are determined according to underlying hard and soft tissues [1].

Major units are the Forehead; Upper – Lower Eyelid; Nose; Cheek; Upper- Lower lip; Chin; Sub-mentum and the Neck (Figure 1).

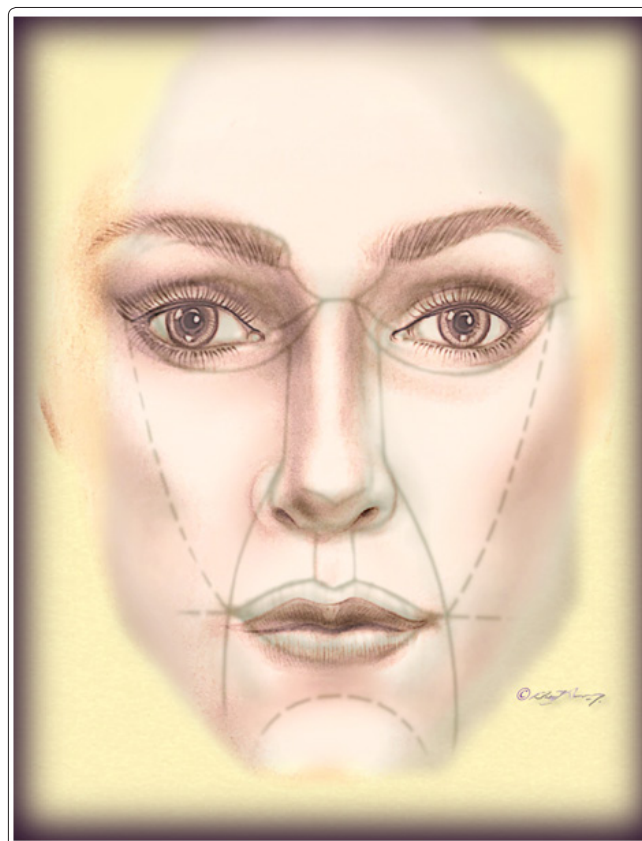


Figure 1: Author's illustration of Facial units based on the original ideas of Gonzalez (1954)

Gonzalez then named those into “Facial Aesthetic regions or units” and were the first who applied the surgical principle of discarding peripheral healthy skin in order to restore it as a unit. They advocated reconstructing the entire nose or forehead, and considered a uniform sheet of a skin flap or even a graft [2].

Millard Jr. have described aesthetic restoration of major nasal defects using the Indian forehead flap and demonstrated it by making templates of the defect and the main units as thirds [3].

The principle of aesthetic “Nasal Subunit” reconstruction by Burget and Menick is well respected and considered to be the excellence of care in nasal reconstruction [4]. They have recognized nine “Subunits” defined also by gentle valleys and low ridges that become apparent with light and shadows. Three are unpaired: Dorsum, Tip and Columella. Other three are paired: Side walls, Alar-nostril sill and the Soft triangles (Figure 2).



Figure 2: Author’s illustration of nasal aesthetic subunits based on Burget G. and Menick F. principle, 1985

They used strategy of Gonzalez and applied it specifically on nasal surface: simply whenever 50% of a subunit as an example the dorsum or soft triangle etc. is affected then the defect should be extended slightly to involve a regular subunit shape, which is then reconstructed using a flap or full thickness skin graft (FTSG).

Supposedly this would maximize camouflage of the transferred tissue and the scar. Those major three contributions (Gonzalez followed by Millard Jr. and then Burget-Menick) converted the nasal reconstruction into a truly artistic procedure. The subunit principle of Burget and Menick was often referred as the (Rule of 50%).

Generally speaking, as per classic teaching, it is well known that Dorsal subunit (by Burget/ Menick) is one of the Nasal areas that are quite encouraging and acceptable to use a (FTSG) [4].

The patient shown in (Figure 3) who has type IV skin presented for a second opinion, he had a history of traumatic skin loss and a postauricular FTSG two years ago. The graft is quite hyperpigmented, has distinct borders and very obvious.

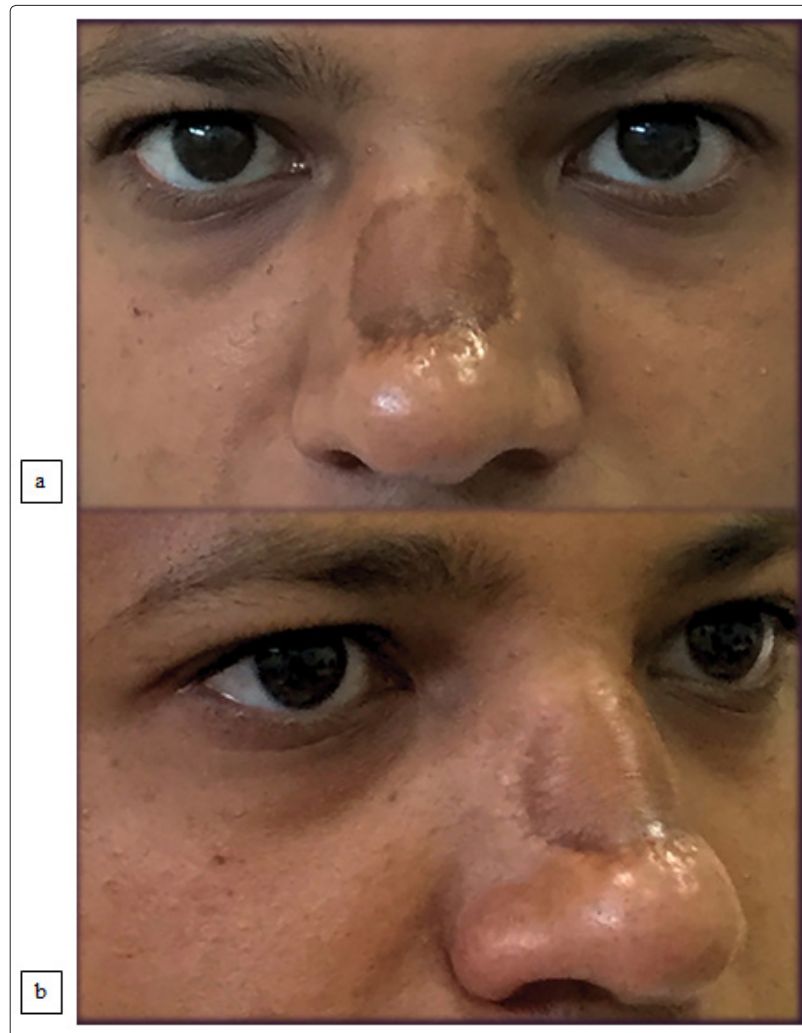


Figure 3: Type IV Skin adult, 2 years post FTSG to dorsal nasal subunit following trauma. The graft is hyperpigmented and very obvious.

a) Frontal view b) Oblique view

Type III skin patients is a dominant type in many parts of the world, the patient shown in (Figure 4), has a history of MVA few years back and presented with this picture of hypertrophic scar over the nasal tip region. Such a complication is also quite unusual for type I and II skin patients. Individuals with skin types ranging from to III to V are prone to scar hyperpigmentation, obvious stitch marks, hypertrophic scars and keloids this is true regardless of the geographical differences [5, 6].

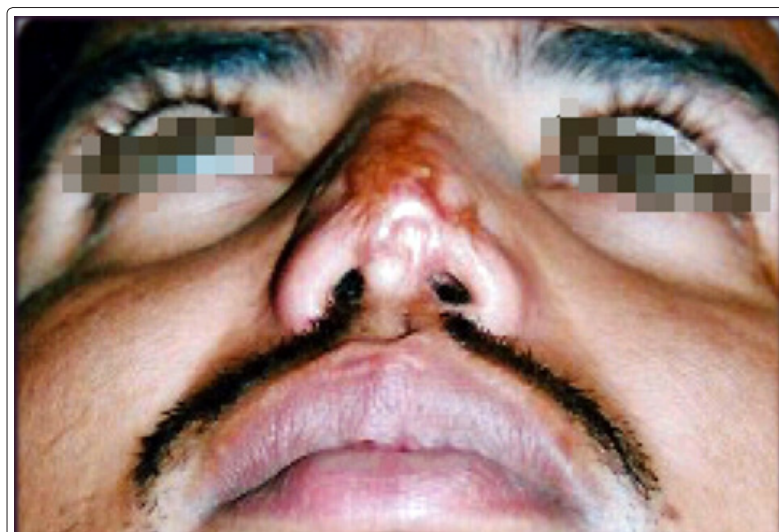

Figure 4: Type III skin type adult, few years post trauma with hypertrophic scars on nasal tip, dorsum and columella

The outcome shown in the above patients is however not by any means one would expect and or accept to see in an average Caucasian type I or type II skin, if they had same scenario. On the other extreme and in comparison to the above cases, a patient is shown in (Figure 5) with BCC on the nasal tip region, which is an area that many would advocate for a flap due to the thick oily nature of skin here as well it is more adherent to underlying cartilage. However, this (type I skin) patient was only treated with simple excision, a FTSG and without applying the 50% rule. The graft is barely noticeable apart from slight hypopigmentation. The obvious explanation is the fair skin type.

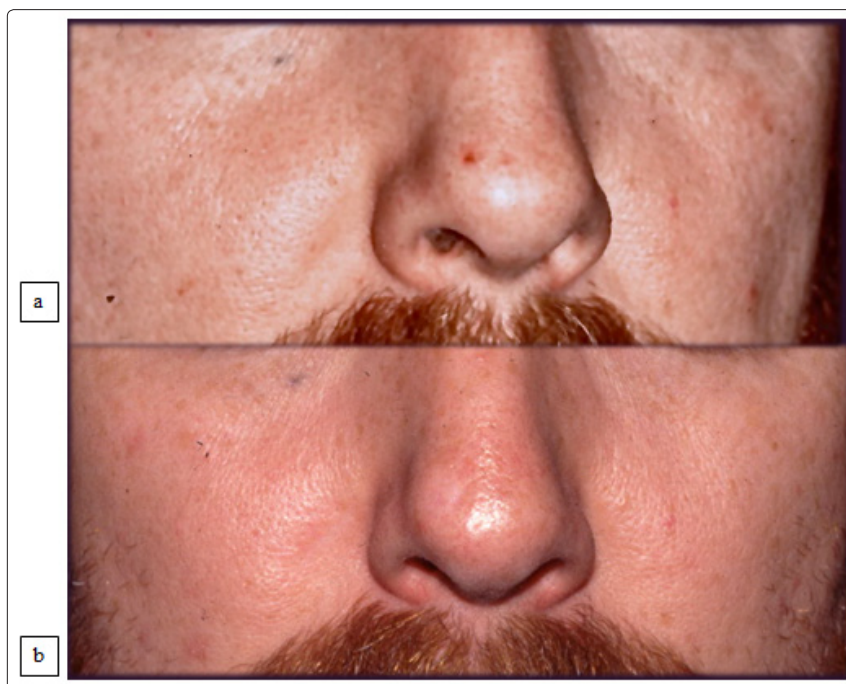

Figure 5: Type 1 skin adult with superficial BCC to nasal tip subunit (a: above) Post FTSG following localized excision without utilizing Subunit principle, with barely noticeable scar, apart from slight graft hypopigmentation (b: below) Courtesy of Dr. M.F. Stranc.

The patient shown in (Figure 6-10) has a skin type V, with history of facial infection as a neonate complicated with significant nasal tissue loss. As a young adult, patient wanted the best possible outcome. A consideration of restoring his overall nasal skin with a Scalping flap as one big unit was given, avoiding any suture lines between subunits otherwise [7].

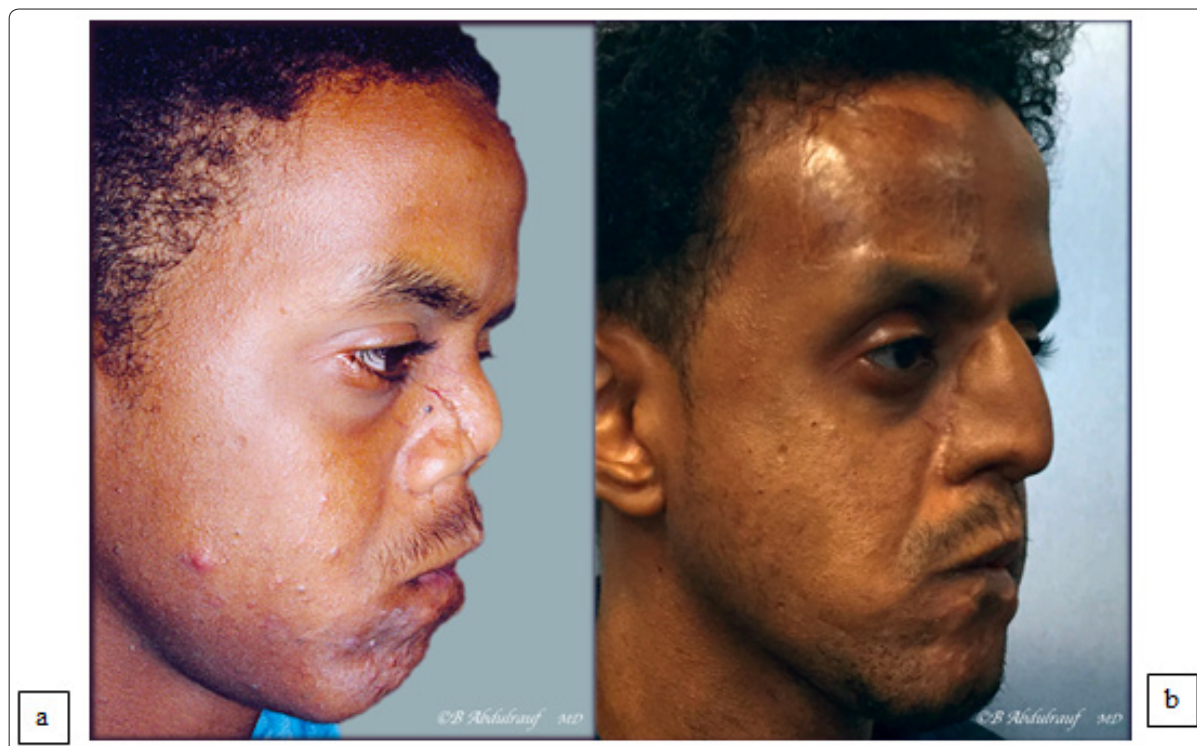

Figure 6: Type V skin, 19 years old, with history of neonatal facial infection and nasal soft tissue loss and atrophy (a). Then 10 years post reconstruction of whole nasal unit with Scalping flap (and a cantilever bone graft), in order to keep suture lines at nasal-facial groove; Has undergone orthognathic surgery as well; Patient is been given option of tissue expansion to replace the skin grafted area on forehead donor site, but he did not seem to be concerned (b).

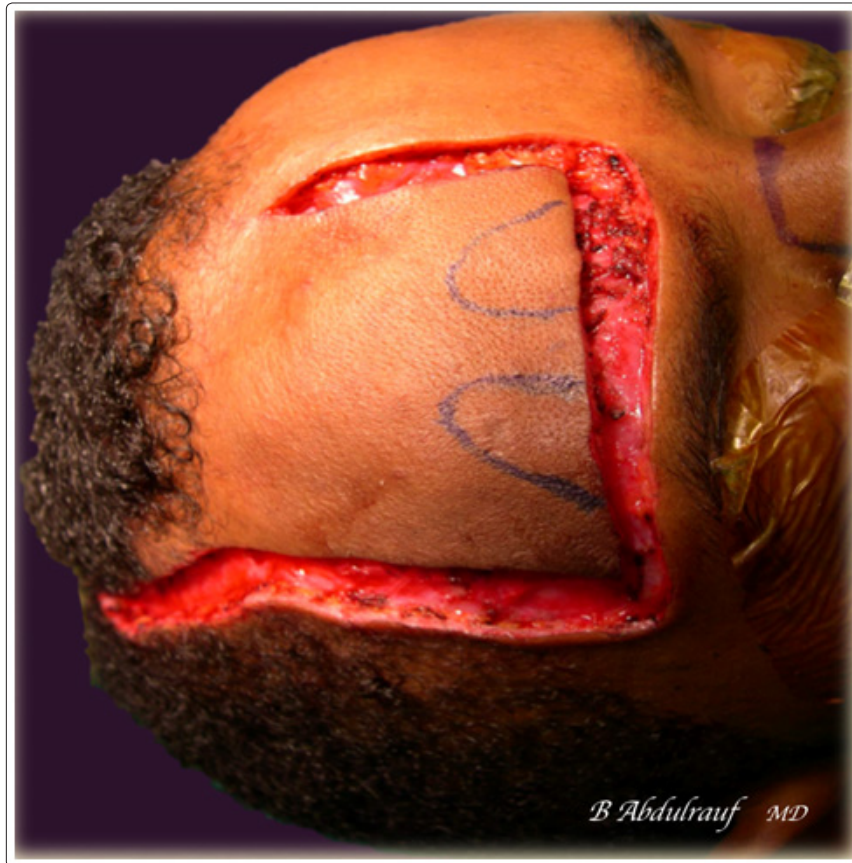

Figure 7: The patient in figure 6 at time of reconstruction. Approximately 7 cm width of unilateral forehead is used in order to accommodate the future nose.

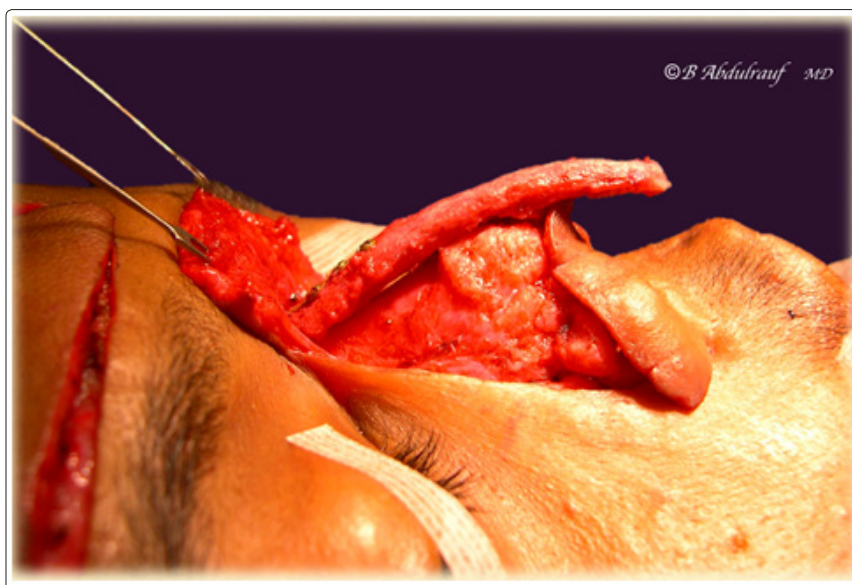

Figure 8: Cantilever graft held to radix with mini-plate and screws. Most of external nasal skin has been discarded.

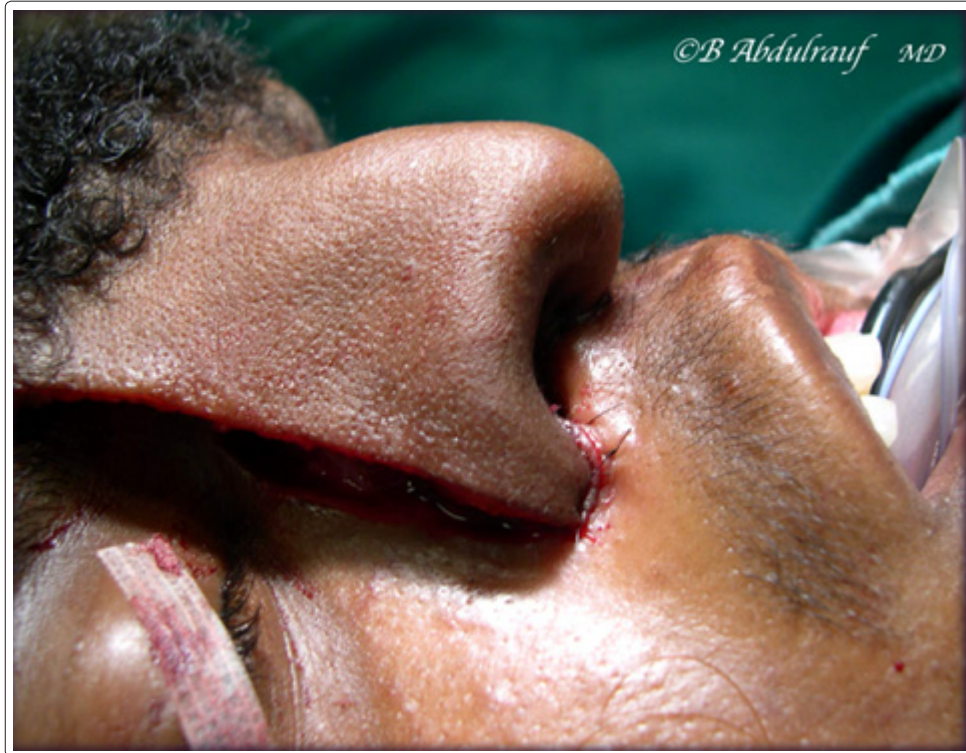

Figure 9: Nasal coverage with Scalping flap. Profile view

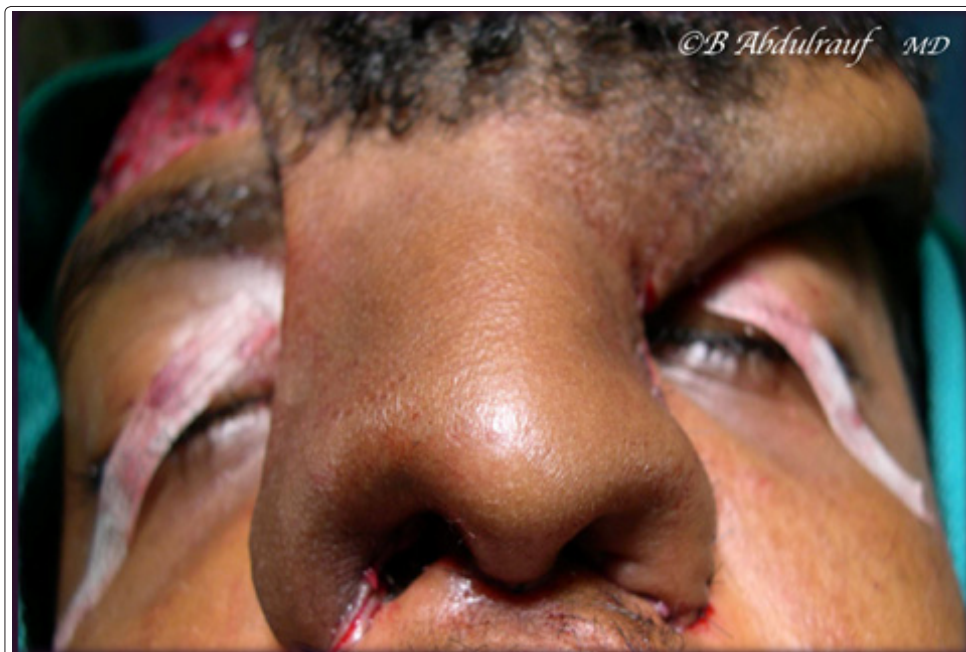

Figure 10: Flap in- setting, basal view

If the nasal lobule or tip region was built as separate subunits the way normally one would with standard paramedian forehead flap utilizing Burget and Menick principles, this patient would have had obvious hyperpigmented scars all over his nose.

The patient in (Figure 11) is a 75year old type IV skin with SCC, who was also considered for total nasal reconstruction and coverage with Scaping flap.

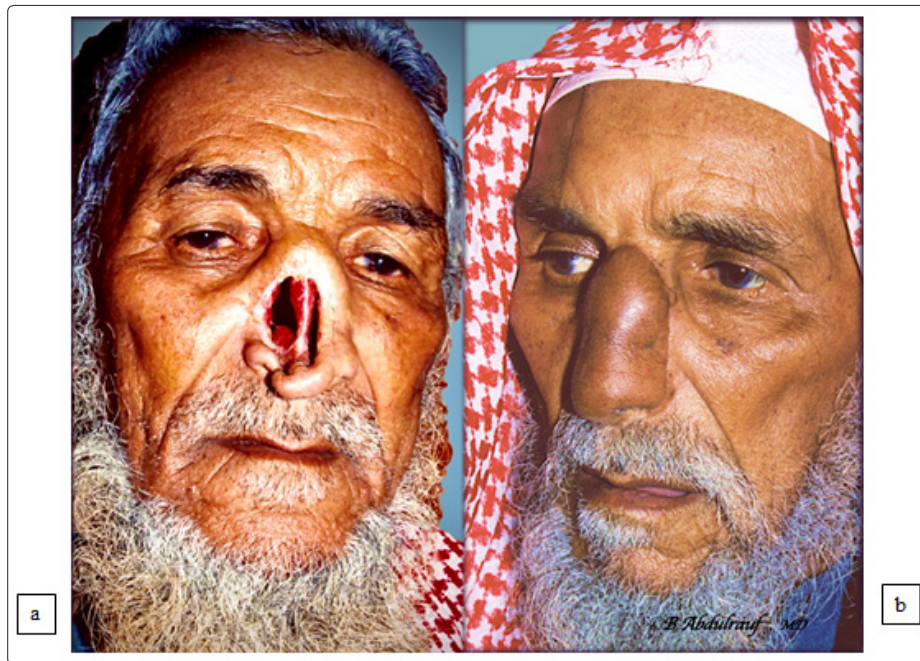

Figure 11: Type IV skin, 75 years old with advanced SCC and significant nasal defect (a). Three months post total nasal reconstruction and coverage with a Scalping flap (b). Edema is still noticeable.

In the oriental patient nasal reconstruction, who are known of their increased risk for abnormal scarring, Hasio et. al. has proposed a modification to the original guidelines by Burget and Menick. They consider discarding extra healthy skin adjacent to subunit, for a better conceal to scars [8].

The overall experience and literature are deficient in nasal reconstruction for types IV and V skin patients, due to the probable reason of less photosensitivity and incidence of skin cancer. Defects due to other reasons are not uncommon but unfortunately still there is not much written.

Singh et al. have analysed their experience in (Caucasian patients) where the subunit principle was violated in 31% of their patients. They looked at multiple factors including practicality, and questioned whether there is even a need for the “50% rule” by Burget and Menick. Cases where the rule was violated (in type I and II patients as per photos), most of them had local flaps with incisions traversing in the middle of subunits. Even though as per their evaluation tool, they had excellent results in 85% of those patients [9].

In day to day practice, close to fifty percent of surgeons in North America once indicated they are not following the subunit rule, simply because they felt they can get good results any ways [10].

This provides enough evidence, in general skin types I and II heal with minimum scarring and pigmentation issues, and their scars are forgiving. With dark patients the situation is exactly the opposite.

Summary

The Subunit principle for nasal reconstruction is suitable mostly for the fair complexion patients. In a dark patient, using such a principle would probably result in a quite undesirable appearance, the abnormal scarring process would not respect any subunits or borders.

This is the reason we do not believe the rule of 50% by Burget and Menick is by any means valid or adequate for the dark patient. Such a principle is to be respected but it should not be dealt with as verse from a holy book.

The original concept by Gonzalez-Ulloa of replacing the entire region or main unit probably suits better the dark complexion patients, as shown above.

In fact, the whole practice of plastic surgery becomes quite different when dealing with types IV and V patients on frequent basis. Unfortunately, the literature has been deficient from this aspect. In terms of nasal reconstruction, **it is unfair for the darker complexion patients to be treated with a general rule made for the fair complexion patients, without considering skin types.**

In saying so, we are not advocating that even for minimal defects to generalize a major reconstruction such as Scalping flap or extended forehead flaps in the dark patients. However, surgeon and the patient have to be aware of what to expect, and be able to explore wider options.

It should also be kept in mind; *Regardless of socioeconomic status, geographical, ethnic or even age differences, all patients coming to Reconstructive plastic surgery, have high expectations.*

Acknowledgement

The Author would like to thank Dr M.F. Stranc, for their courtesy in providing an example of Type I skin patient, nasal tip outcome with FTSG (Fig. 4).

References

1. Gonzalez-Ulloa M, Castillo A, Stevens E, G Alvarez Fuertes, F Leonelli, et al. (1954) Preliminary study of the total restoration of the facial skin. *Plast. Reconstr. Surg* 13: 151-161.
2. Gonzalez-Ulloa M (1956) Restoration of the face covering by means of selected skin in regional aesthetic units. *Br. J. Plast.*

-
- Surg 9: 212-221.
 3. Millard DR (1976) Reconstructive rhinoplasty for the lower two thirds of the nose. 1976 Plast. Reconstr. Surg. 57: 722-728.
 4. Burget GC and Menick FJ (1985) The subunit principle in nasal reconstruction. Plast. Reconstr. Surg 76: 239-247.
 5. Fitzpatrick TB, Seiji M and McGugan AD (1961) Melanin pigmentation(cont.). 1961 New England J. Med 265: 274-278.
 6. Morgan JE, Gilchrest B, Goldwyn RM (1975) Skin pigmentation. Current concepts and relevance to plastic surgery 56: 617-682.
 7. Converse JM and McCarthy JG (1981) The scalping flap revisited, Clin. Plast. Surg 8: 413
 8. Hasio Y-Chang, Chang CS, Zelken J (2017) Aesthetic refinements in forehead flap reconstruction of the Asian nose. Plastic surgery (Oakv) 25: 71-77.
 9. Singh DJ, Bartlett SP (2003) Aesthetic considerations in nasal reconstruction and role of modified nasal subunits. Plast. Reconstr. Surg 3: 639-648
 10. Hackler F, Jelks G, Persing J, Pribaz J (2000) Facial defects after Moh's surgery and trauma: Options for reconstruction. Presented at the 17th Annual meeting of northern society of plastic surgeons, in Montreal Canada, Sept. 2000.