

## Case Report

## Open Access

# Lemierre's Syndrome Resulting from Cholesteatomatous Otitis Media and Mastoiditis: A Case Report

Niema Benkhraba<sup>1,3\*</sup>, Razika Bencheikh<sup>2,3</sup>, Lina El Messaoudi<sup>1,3</sup>, Mohamed Anas Benbouzid<sup>2,3</sup> and Leila Essakalli Houssyni<sup>2,3</sup>

<sup>1</sup>Resident Physician in Otorhinolaryngology, Department of Otorhinolaryngology, Head and Neck Surgery, Ibn Sina University Hospital, Rabat, Morocco

<sup>2</sup>Professor of Otorhinolaryngology, Department of Otorhinolaryngology, Head and Neck Surgery, Ibn Sina University Hospital, Rabat, Morocco

<sup>3</sup>Faculty of Medicine and Pharmacy of Rabat, Mohammed V University, Rabat, Morocco

### ABSTRACT

Lemierre's syndrome is a rare and in some cases fatal thrombophlebitis of the internal jugular vein (IJV). It usually follows acute oropharyngeal or otologic infections in healthy, young children. *Fusobacterium necrophorum* is the most common bacteria that causes Lemierre's syndrome, whereas various microorganisms are reported. We report a case of Lemierre's syndrome secondary to chronic otitis media, which remains a rare occurrence of a very seldom disease.

### \*Corresponding author

Niema Benkhraba, Department of Otorhinolaryngology, Head and Neck Surgery, Ibn Sina University Hospital, Rabat, Morocco.

E-mail: mohamed.ali.gliti@gmail.com

**Received:** March 28, 2022; **Accepted:** April 04, 2022; **Published:** April 13, 2022

**Keywords:** Lemierre's Syndrome, Otitis Media, Jugular Vein, Thrombophlebitis

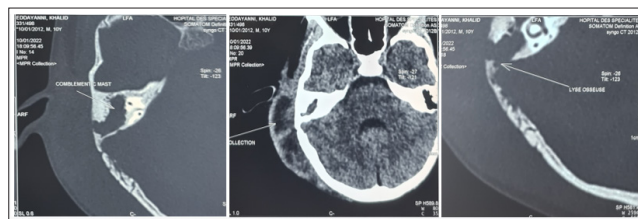
### Introduction

The Lemierre's syndrome, or necrobacillosis, is a disease rare defined as septic thrombophlebitis of the internal jugular vein or one of its branches, associated to septic emboli. This sepsis is due to *Fusobacterium necrophorum* secondary to an infection of the ENT sphere, most often oropharyngeal [1]. Chronic otitis media is exceptional, and must however be mentioned, since its ignorance can delay the diagnosis. The morbidity is related to time to treatment. We report one case of Lemierre's syndrome complicating chronic cholesteatomatous otitis media.

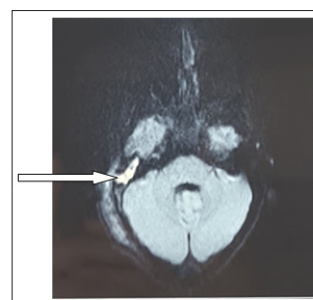
### Case report

We report the case of a 9-year-old child admitted to the emergency room for otomastoiditis. The history of his illness dates back to 8 months with the appearance of fetid purulent otorrhea in the right ear, complicated by right retro-auricular swelling with headaches, torticollis, diplopia and fever. The clinical examination finds a painful hot red right retroauricular tumefaction. The microscopic examination found a right atticite with an attic polyp and cholesteatoma lamellae. The computed tomography scan showed a right malignant otitis complicated by a retro-auricular collection, osteomyelitis of the wall of the homolateral sigmoid sinus (Figure 1). A cerebral MRI was performed showing right otomastoiditis complicated by septic thrombosis of the ipsilateral internal jugular vein extending from the gulf to the sigmoid sinus, and a right retro-auricular

collection (Figure 2). Cytobacteriological examination isolated *Klebsiella pneumoniae*. The patient has received bi-antibiotic therapy based on C3G and metronidazole associated with anticoagulant treatment, with good clinical and biological evolution. The patient then underwent surgical treatment of his cholesteatoma, with canal wall up mastoidectomy; the postoperative course was good.



**Figure 1:** CT scan of the head



**Figure 2:** Magnetic resonance imaging of the head: Right jugular venous thrombosis and right transverse sinus thrombosis (Arrow)

Lemierre's syndrome is defined as septic thrombophlebitis of the vein internal jugular or one of the collateral veins, originally septic emboli, following an ENT infection, and which results in hematogenous invasion by anaerobic bacteria, *Fusobacterium necrophorum* [1]. It is an anaerobic bacterium Gram-negative, communal of the oropharynx, tube digestive system and the female genitalia. Its pathogenicity would be secondary to the release of endotoxins that promote the spread of the infection to the surrounding tissues, then to the cervical region until causing thrombosis of the vein internal jugular and/or its branches [1].

Clinically, Lemierre's syndrome evolves in two phases. The initial phase corresponds to the ENT infection, which is the more often oropharyngeal (simple or complicated angina peritonsillar phlegmon, cervical lymphadenopathy and febrile syndrome) [1,2]. The starting point is rarely otological, as in our observation. The second phase corresponds to the spread of the infection to the parapharyngeal spaces, with thrombophlebitis of the jugular vein and sepsis [3]. It manifests itself in the week following the initial infectious episode, but is likely to appear later, which can pose diagnostic problems [1,2]. Clinically, it results in febrile peaks with chills, poor general condition, torticollis and tenderness cervical homolateral to the initial location. The clinical examination finds a painful and inflammatory induration of the region sterno-cleido-mastoid, which can progress to cellulitis cervico-mediastinal. Sometimes only a palpable induration is found at the front of the sterno-cleido-mastoid, corresponding to the thrombosis venous. The general signs, generally very marked, include pulmonary symptoms (cough, thoracopleural pain, dyspnea, hemoptysis) and arthralgia. Septic emboli can be localized at the level of all the organs, especially liver and kidneys. Cases of endocarditis have also been reported [3]. However, when the starting point is otitic, metastatic infectious manifestations are exceptional; however, cases of meningitis can be found associated [4].

Biology shows an important inflammatory syndrome with hyperleukocytosis in all cases. Hyperbilirubinemia is found in 50% of cases, secondary to hepatolysis, and disseminated intravascular coagulation in 23% of cases [1]. Bacteriological samples, in particular blood cultures, make it possible to find the germ in question (*Fusobacterium necrophorum*), but, in 10 to 30% of cases, a polymicrobial flora is found and, in 10 to 15% of cases, no germ is identified [1,2]. In our case, *Klebsiella pneumoniae* was identified in otorrhea.

Imaging plays an important role in showing impairment both ENT and pulmonary [6]. Cervical CT with injection of contrast agent objective thrombophlebitis of the vein internal jugular, but also the adenopathies [5,6]. Doppler ultrasound can visualize thrombosis venous in the form of a vein increased in diameter, incompressible, and an absence of blood flow. However, this examination is operator-dependent, it does not allow to visualize the whole of the internal jugular vein and may not show a fresh, unorganized thrombus. Chest X-ray or, better, thoracic CT looks for septic emboli under form of peripheral parenchymal nodules with or without cavitation and pulmonary condensation areas [7].

Most authors recommend parenteral antibiotic therapy, based on clindamycin, or second or third cephalosporin generation, associated with metronidazole. This antibiotic therapy should be continued for 2 to 6 weeks, adapted to the antibiogram with observation of clinical improvement and normalization of the biological parameters. Surgical drainage should be done whenever there is a deep abscess. Also a canal wall up

mastoidectomy should be performed for the cholesteatoma. The treatment anticoagulant is discussed: indeed, it risks promoting septic emboli by fragmentation of the venous thrombus, but remains the only way to avoid a retrograde progression of the thrombus to the cavernous sinus. The terms of prescription anticoagulants are poorly defined [1,8].

The prognosis of Lemierre's syndrome depends on the time elapsed before the diagnosis and the start of treatment. Mortality has become exceptional since the advent of antibiotics [8].

## Conclusion

Lemierre's syndrome is a rare and serious condition, secondary to an infection of the ENT sphere, reaching young children and in good general condition. The otic origin of this condition is rarely reported in the literature; however, you have to think to this possible complication of otitis media, since only early management allows a favorable evolution. There is no consensus on treatment, but antibiotic therapy broad-spectrum, long-term parenteral therapy appears to provide good results.

## References

1. Righini CA, Hitter A, Perrin MA, Schmerber S, Ferretti G, et al. (2006) Lemierre's syndrome: literature review. *Ann Otolaryngol Chir Cervicofac* 123: 179-188.
2. Rosique Lopez L, Rodriguez Dominguez F, Navarro Paule P, Soler Valcarcel A (2007) Lemierre's syndrome: an unusual variant. *Acta Otorrinolaringol Esp* 58: 217-218.
3. Fiesler FW, Richman PB, Riggs RL (2001) Pharyngitis followed by hypoxemia and sepsis: Lemierre's syndrome. *Am J Em Med* 19: 320-322.
4. Masterson T, El-Hakim H, Magnus K, Robinson J (2005) A case of the otogenic variant of Lemierre's syndrome with atypical sequelae and a review of the pediatric literature. *Int J Pediatr Otorhinolaryngol* 69: 117-122.
5. Lemierre's A (1936) On certain septicaemias due to anaerobic organisms. *Lancet* 230: 701-703.
6. Perrin MA, Jankowski A, Righini C, Boubagra K, Coulomb M, et al. (2007) Syndrome de Lemierre's : apport de l'imagerie. *J Radiol* 88: 65-68.
7. Nguyen-Dinh KV, Marsot-Dupuch K, Portier F, Lamblin B, Lasjaunias P, et al. (2002) Lemierre's syndrome: usefulness of CT in detection of extensive occult thrombophlebitis. *J Neuroradiol* 29: 132-135.
8. Brook I (2003) Microbiology and management of deep facial infections and Lemierre's syndrome. *ORL J Otorhinolaryngol Relat Spec* 65: 117-120.