

## Research Article

## Open Access

## Hyoid Bone also Known as Suicide Bone – A Case Report

Ashwin Singh Chouhan\* and Bhuvanesh Baniya

Jai Narain Vyas University Jodhpur, Rajasthan India

### ABSTRACT

**Objective:** The goal of this paper is to provide a case of traumatic hyoid bone fracture as well as a literature review. Rationale: Traumatic hyoid bone fractures are uncommon; but, as martial arts become more popular, the incidence of traumatic hyoid bone fractures may rise.

**Clinical Characteristics:** After getting a kick to the anterior neck, a thirteen-year-old taekwondo athlete fell. Following immediate first-aid treatment, the athlete complained of difficulty speaking and swallowing, as well as breathlessness. Over the hyoid bone, there was ecchymosis and soreness.

**Intervention and Result:** Lateral radiographs indicated a hyoid fracture. The patient was given analgesics and told to rest at home. At four weeks after the injury, the athlete was cleared to return to sports.

**Conclusion:** In the management of suspected bone fractures, ensuring airway integrity and screening for symptoms of laryngeal laceration are critical. It is strongly advised that you observe for 48-72 hours. (JCCA 2012; 56(4):269-274)

### \*Corresponding author

Ashwin Singh Chouhan 587, Daulat Niwas 10<sup>th</sup> B Road Sardarpura, Jodhpur (Raj.) 342003, India. Tel: 8209721229;  
E-mail: ashwinsingh26061992@gmail.com

**Received:** December 22, 2021; **Accepted:** December 29, 2021; **Published:** January 05, 2022

**Keywords:** Hyoid, Fracture, Trauma, and Martial Arts

### Introduction

#### Problem formulation

Introduction The world of mixed martial arts (MMA) is continually increasing in popularity; with the Ultimate Fighting Championship (UFC) being the world's largest promoter of MMA. In the past 10 years the number of UFC events per year has increased from 6 in 2000 to 24 in 2010, and has currently set North American live-gate records at UFC 129 with an attendance of 55,724 totaling 11.5 million Canadian dollars [1,2]. A viewership of 1.5 million was recorded for the live aired fights on cable television before the main event [3]. All of the 24 fighters involved in the event received medical suspensions, 7 of which were related to knockouts or serious trauma to the head region [4].

Due to the increasing popularity of MMA, it is essential to understand the injury profiles for which these athletes are at risk. In 2007 a five year retrospective cohort study reported 19.0% of injuries sustained by MMA athletes were to the head and neck regions [5]. In a report of 116 MMA fights over seven years, it was reported that 29.1% of injuries were to the head and neck regions [6]. Kochhar et al. reported on several maneuvers commonly used within MMA, and showed that they share similar kinematic features as those who sustain a rear impact motor vehicle accident. They concluded that due to the similar kinematic profiles MMA athletes may be at risk for cervical spine injuries commonly seen in rear impact motor vehicle accidents [7].

Analysis of individual martial arts used in MMA can provide further insight into risks of injury. Taekwondo is a martial art form

involving strikes and kicks to an opponent, with more points in a match being awarded for a kick impacting the head [8]. Head and neck injury rates within taekwondo have been found to be similar to those found in MMA. A 1997 analysis of a national level taekwondo even showed that 9.2% of injuries sustained were to the head and neck regions [9]. In a 2009 retrospective longitudinal study of taekwondo injuries, it was found that over a 9 year period 23.3% of injuries were to the head and neck [10]. This information may suggest that there has been an increase in the prevalence of head and neck injuries within the martial art of taekwondo.

Many structures exist within the head and neck region which may be susceptible to injury during a MMA fight. The hyoid bone is a U-shaped bone situated in the anterior portion of the neck [11,12]. Hyoid bone fractures, or Garrotter's Throat, are very rare [13,14]. The incidence of fracture of the hyoid bone is reported as being 0.002% of all fractures; however this statistic appears to be determined anecdotally from references as far back as 1949 [14-17]. These incidence statistics may not be representative of today's society, especially considering the increasing popularity of MMA and the associated rates of head and neck trauma previously reported.

A case of traumatic fracture of the hyoid bone in a taekwondo athlete is presented. To the author's knowledge this is the first case of hyoid bone fracture associated with taekwondo.

### Case Presentation

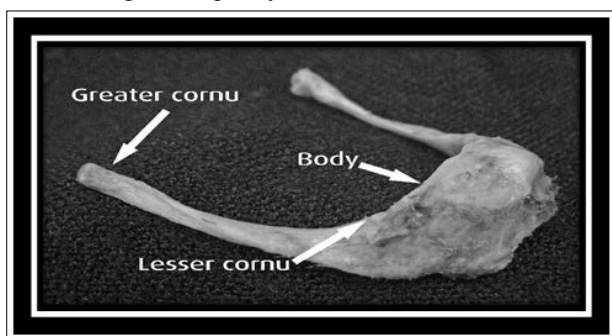
A thirteen year old male provincial level black belt taekwondo athlete was kicked in the anterior aspect of the throat during a match. The athlete fell prone onto the mat and was immediately assessed by the medical staff for breathing and any cervical spine trauma. Immediately

after the kick the athlete reported severe neck pain, particularly in the anterior region. The neck was stabilized and a full examination including sensory and motor examination was conducted and reported as unremarkable. There was no loss of consciousness and Glasgow Coma Scale was rated as 15/15. The patient's pupils were equal and reactive to light and upon palpation there was no midline bony tenderness in the cervical spine. Since signs of severe spinal trauma were ruled out, the athlete was carefully log-rolled to the supine position with cervical spine stabilization.

The athlete was otherwise healthy with no previous cervical spine or anterior throat trauma. Systems review was performed and was unremarkable with no other significant complaints. No numbness or tingling into the upper or lower extremities was reported. The medical staff proceeded to remove the chest and head protection for further inspection of the chest and anterior neck. At this point edema was noted on the anterior aspect of the neck at the level of the larynx. The primary pain was directly located to the hyoid bone in the anterior aspect of the neck. Vital signs including blood pressure, heart rate, and respiratory rate were within normal limits. A complete neurological examination of the upper and lower limbs was completed off the mat at the medic station including reflexes, sensation, and motor function. Deep tendon reflexes at C5, C6, C7, L4, S1 were graded as 2+ bilaterally, sensation was unremarkable in all dermatomes, and the motor examination was graded as 5/5 bilaterally in C5, C6, C7, C8, T1, L4, L5, S1. Capillary refill was <2 seconds in the fingernails and toenails.

Observation of the cervical spine was unremarkable. Due to the absence of neurological compromise and osseous tenderness in the cervical spine, the lead medical coordinator deemed it appropriate to proceed with further physical assessment of the athlete. Active range of motion in the cervical spine revealed full and pain-free flexion, bilateral lateral rotation, and bilateral lateral flexion. Pain was experienced in the anterior aspect of the neck localized to the hyoid bone with full terminal extension. Passive range of motion of the cervical spine revealed identical findings as the active range of motion testing. Resisted cervical range of motion was pain-free in all ranges. Observation and palpation of the mandible was unremarkable.

Observation at the level of the cricoid cartilage and larynx revealed slight edema. There was no obvious deviation of the trachea, larynx, or cricoid cartilage. Palpation of the cricoid cartilage, larynx, and hyoid bone reproduced chief complaint. The cricoid cartilage moved superiorly when the patient was asked to swallow however recreated pain in the anterior neck. A stethoscope examination was performed directly over the cricoid cartilage and trachea revealing stridor and wheezing. Hoarseness was noted while assessing voice quality.



**Figure 1:** Cadaveric Dissection of the Hyoid Bone

## Discussion

### Anatomy

The hyoid bone is located in the anterior neck at the level of the C3 vertebra between the thyroid cartilage and the mandible [11]. It is suspended by the stylohyoid ligaments as well as muscles attaching to the mandible, styloid processes, thyroid cartilage, manubrium and scapulae [11,12]. The hyoid is composed of five sections; the body, Figure 1: Cadaveric dissection of the hyoid bone [2]. 272 J Can Chiropr Assoc 2012; 56(4) Traumatic hyoid bone fracture – a case report and review of the literature greater and 2 lesser cornua [11,12]. The lesser cornua is attached to the body via fibrous tissue and in some cases by a synovial joint. The lesser cornua itself can remain a cartilaginous structure well into adulthood [11]. Functionally the hyoid provides a movable base for the tongue, attachment points for the middle pharynx and maintains patency of the pharynx, required during swallowing and respiration [11]. In males the greater and lesser cornua fuse to the body of the hyoid bone unilaterally at 38.25 and bilaterally at 53.16 years of age respectively while females achieve bony fusion unilaterally and bilaterally at 38.00 and 48.50 years of age respectively [18].

### Mechanism of Injury

Fracture of the hyoid is typically associated with strangulation [12,15,17,19-25]. Traumatic cases do exist in the literature and include mechanisms such as blunt trauma, hyperextension, gunshot, motor vehicle accidents, induced vomiting, cervical trauma, and one case involving a headlock [15-17,26-37]. Based on this information, striking and choking techniques commonly employed in martial arts provide potential mechanisms for hyoid bone fractures. It is thought that the rarity of this condition is due to the protection it receives from the mandible as well as from its mobility [12,17]. In situations where hyperextension is induced the hyoid bone is exposed and may be at greater risk for blunt trauma [17]. This position also places many of the muscles attaching to the hyoid bone under tension, decreasing the mobility of the hyoid and potentially reducing its mobility and thus its ability to absorb forces.

The age at which the hyoid bone fuses has been suggested as another protective factor [17,18]. Prior to fusion, the elastic cartilaginous structure of the hyoid may offer protective mobility when exposed to trauma [17]. The average age of presentation for a hyoid bone fracture has been reported to range from 15 to 55 with an average age of 35. A much higher prevalence in men than women has been identified [17]. This would suggest that despite the suggested mechanisms afforded by a lack of fusion these fractures still occur. Perhaps it is the activities being undertaken by individuals in this age range that is of importance rather than the age of fusion.

In the present case, blunt direct trauma in the form of a kick was delivered to the hyoid bone resulting in hyper extension of the head. The age of the patient would suggest a possible protective effect due to the absorption of force afforded by the elastic cartilaginous hyoid. The case highlights that the activity involved may represent a more important role in predicting the presence of a hyoid bone fracture than the patient age and degree of fusion of the hyoid bone.

### Patient Presentation

The primary presenting symptom of hyoid bone fracture patients is sharp anterior neck pain aggravated by talking, nose blowing, coughing and swallowing. 12,15,17,38,39 Dysphagia associated pain is worse when swallowing solids compared to fluids. 12,17

Changes in voice quality such as lowered pitch and hoarseness have also been reported along with dyspnea, stridor and crepitus in the neck [12,15,17,39-41]. It has been reported that cases resulting from muscular force such as hyperextension injuries may report a snapping or give way sensation [12]. In situations where sharp ends of the hyoid cause laryngeal lacerations and prevertebral muscle damage symptoms of hemoptysis, subcutaneous emphysema and ecchymosis are commonly noted [15]. There may be pain with palpation of the anterior neck and hyoid with pain during cervical spine ranges of motion [15]. Concomitant injuries may include mandibular fractures, facial fractures, thyroid cartilage fractures, cervical spine injuries, facial lacerations and external carotid artery pseudoaneurysm [15,42].

The patient in the present case experienced anterior neck pain aggravated by swallowing, palpation and neck extension. Dyspnea, stridor and hoarseness in the voice were all noted. There was no evidence of hemoptysis, subcutaneous emphysema or ecchymosis. The presenting symptoms are suggestive of a hyoid bone fracture with no evidence of laryngeal laceration.

### Diagnosis

Diagnosis is typically made using clinical findings along with a radiograph, CT scan, direct laryngoscopy, nasendoscopy or surgical inspection [15,17,38,40]. As in the presented case, radiographs are typically taken in a lateral orientation and must reveal a radiolucent line, interruption of the cortex or displaced fragments to diagnose a hyoid bone fracture [15,17]. Fractures are typically seen in the body or the greater cornua of the hyoid [17]. Direct laryngoscopy is recommended where dyspnea, hemoptysis or laryngeal lacerations are present to assess for pharyngeal J Can Chiropr Assoc 2012; 56(4) 273 J Porr, M Laframboise, M Kazemi integrity and to assess for any bony protrusion [15,17]. In some situations it may be beneficial to employ a Valsalva maneuver during laryngoscopy as it may further highlight any deformity [40].

### Treatment

All patients suffering a hyoid bone fracture must be observed for a 48-72 hour period as previously asymptomatic patients may develop rapid hemoptysis, edema, ecchymosis and spasm resulting in life threatening asphyxia, requiring a tracheostomy and retro-pharyngeal drainage [15,17,38].

Treatment is typically dependant on whether or not there is perforation of the larynx or pharynx [12]. In cases where no perforation exists conservative treatment is employed [12]. Typically no reduction of the fracture is needed [12,15]. Diet may be restricted to liquids until dysphagia subsides, or in more extreme cases a feeding tube may be inserted [12,15,38]. Ice and analgesics may be employed to control ecchymosis and pain [15,17]. Where there is larynx or pharynx perforation, removal of the fractured hyoid and any fragments as well as suturing and fixation may be warranted [15,17,40]. With soft tissue compromise the risk of infection does exist, as such body temperature should be monitored [15]. As with conservative therapy, a liquid diet, resting of the voice and possible nasogastric feeding tube may be implemented [15]. Treatment for the presented case was in agreement with previously outlined treatments for hyoid bone fractures not involving laryngeal laceration [12,15,17,40]. Due to the presenting symptoms of the patient the ambulance was called for fear of increasing dyspnea and possible asphyxia.

### Prognosis

Even in cases of non-union, the prognosis for hyoid bone fractures is good [17,31]. Prognosis in cases involving laryngeal laceration

may be less favorable due to underlying complications such as increased edema, hemoptysis, dyspnea and risk of infection. While osseous healing in any fracture typically occurs in 6 weeks, symptom resolution for a hyoid fracture has been reported at 2 – 8 weeks [16,29,31,39,41]. The patient in the present case had full resolution of symptoms by 4 weeks.

### Summary

Traumatic fractures of the hyoid bone are a rare occurrence with potentially fatal consequences. In these individuals, airway preservation is critical, and a 48-72 hour observation period is advised. Although direct laryngoscopy is the best way to see laryngeal lacerations, some presenting symptoms can raise a clinician's suspicion. An excellent prognosis is projected with minor dietary and activity changes. The growing popularity of mixed martial arts (MMA) necessitates that practitioners avoid potential injuries that may begin to become more common.

### References

1. Ultimate Fighting Championship (2011) www.ufc.com 8-5-2011.
2. Stupp D (2011) UFC 129 sets attendance and live-gate records: 55,724 for \$12.1 million. 1-5-2011. 8-5-2011.
3. Stupp D (2011) Spike TV draws 1.5 million viewers for UFC 129 "UFC Prelims" special.
4. UFC 129 (2011) medical suspensions: St-Pierre, Hominick, Couture and Brilz out 60 days. 2-5-2011. 8-5-2011.
5. Ngai KM, Levy F, Hsu EB (2008) Injury trends in sanctioned mixed martial arts competition: a 5-year review from 2002 to 2007. Br J Sports Med 42: 686-689.
6. Scoggin JF, III, Brusovanik G, Pi M, Izuka B, Pang P, et al. (2010) Assessment of injuries sustained in mixed martial arts competition. Am J Orthop (Belle Mead NJ) 39: 247-251.
7. Kochhar T, Back DL, Mann B, Skinner J (2005) Risk of cervical injuries in mixed martial arts. Br J Sports Med 39: 444-447.
8. Taekwondo (2011) <http://www.olympic.ca/en/sports/Taekwondo/> 8-5-2011. Ref Type: Online Source
9. Kazemi M, Pieter W (2004) Injuries at the Canadian National Tae Kwon Do Championships: a prospective study. BMC Musculoskelet Disord 5: 22.
10. Kazemi M, Chudolinski A, Turgeon M, Simon A, Ho E, et al. (2009) Nine year longitudinal retrospective study of Taekwondo injuries. J Can Chiropr Assoc 53: 272-281.
11. Moore KL, Dalley AF (2006) Clinically Oriented Anatomy. 5th ed. Baltimore: Lippincott Williams & Wilkins; 2006.
12. Olmstead EG (1949) Fractures of the hyoid bone; presentation of two cases, with a review of the literature. Arch Otolaryngol 49: 266-274.
13. Davis HJ (1910) Fracture in hyoid bone in a man aged 56 ("Garrotter's Throat"). Proc R Soc Med. 1910; 3(Laryngol Sect):77.
14. Guernsey LH (1954) Fractures of the hyoid bone. J Oral Surg (Chic) 12: 241-246.
15. Bagnoli ML, Leban SG, Williams FA (1988) Isolated fracture of the hyoid bone: report of a case. J Oral Maxillofac Surg 46: 326-328.
16. Chowdhury R, Crocco AG, El-Hakim H (2005) An isolated hyoid fracture secondary to sport injury. A case report and review of literature. Int J Pediatr Otorhinolaryngol. 69: 411-414.
17. Dalati T (2005) Isolated hyoid bone fracture. Review of an unusual entity. Int J Oral Maxillofac Surg 34: 449-452.
18. Gupta A, Kohli A, Aggarwal NK, Banerjee KK (2008) Study of age of fusion of hyoid bone. Leg Med (Tokyo) 10: 253-256.

19. Charoonnate N, Narongchai P, Vongvaivet S (2010) Fractures of the hyoid bone and thyroid cartilage in suicidal hanging. *J Med Assoc Thai* 93: 1211-1216.
20. Demirci S, Dogan KH, Erkol Z, Gunaydin G. Ligature strangulation deaths in the province of Konya (Turkey). *J Forensic Leg Med*. 2009; 16(5):248-252.
21. Fineron PW, Turnbull JA, Busuttil A (1995) Fracture of the hyoid bone in survivors of attempted manual strangulation. *J Clin Forensic Med* 2: 195-197.
22. Green H, James RA, Gilbert JD, Byard RW (2000) Fractures of the hyoid bone and laryngeal cartilages in suicidal hanging. *J Clin Forensic Med*. 2000; 7(3):123-126.
23. Nikolic S, Micic J, Atanasijevic T, Djokic V, Djonic D (2003) Analysis of neck injuries in hanging. *Am J Forensic Med Pathol* 24: 179-182.
24. Sharma BR, Harish D, Sharma A, Sharma S, Singh H (2008) Injuries to neck structures in deaths due to constriction of neck, with a special reference to hanging. *J Forensic Leg Med* 15: 298-305.
25. Ueno Y, Asano M, Nushida H, Nakagawa K, Adachi J, et al. (2003) Sexual asphyxia by hanging – a case report and a review of the literature. *Leg Med (Tokyo)* 5: 175-180.
26. Bux R, Padosch SA, Ramsthaler F, Schmidt PH (2006) Laryngo-hyoid fractures after agonal falls: not always a certain sign of strangulation. *Forensic Sci Int* 156: 219-222.
27. Rash W (2011) Hyoid/Thyroid fracture. *J Emerg Nurs* 37: 182-183.
28. Gross M, Eliashar R (2004) Hyoid bone fracture. *Ann Otol Rhinol Laryngol* 113: 338-339.
29. Dickenson AJ (1991) Fracture of the hyoid bone following minimal trauma. *Injury* 22: 420-421.
30. Bux R, Padosch SA, Ramsthaler F, Schmidt PH (2006) Laryngo-hyoid fractures after agonal falls: not always a certain sign of strangulation. *Forensic Sci Int* 156: 219-222.
31. Padgham ND (1988) Hyperextension fracture of the hyoid bone. *J Laryngol Otol*. 1988; 102: 1062-1063.
32. Kaufman HJ, Ciraulo DL, Burns RP (1999) Traumatic fracture of the hyoid bone: three case presentations of cardiorespiratory compromise secondary to missed diagnosis. *Am Surg* 65: 877-880.
33. Zendeherouh P, Tandon M, Frankel H, Rabinovici R. Hyoid bone fracture from a gunshot wound. *J Trauma*. 2003; 55(5):1003.
34. Kuo LC, Lin HL, Chen CW, Lee WC. Traumatic hyoid bone fracture in patient wearing a helmet: a case report. *Am J Emerg Med*. 2008; 26(2):251-252.
35. Szeremeta W, Morovati SS. Isolated hyoid bone fracture: a case report and review of the literature. *J Trauma*. 1991; 31(2):268-271.
36. Gupta R, Clarke DE, Wyer P. Stress fracture of the hyoid bone caused by induced vomiting. *Ann Emerg Med*. 1995; 26(4):518-521.
37. Anthony R, Martin-Hirsch D, England J. Dysphagia secondary to iatrogenic hyoid bone fracture. *Br J Neurosurg*. 2000; 14(4):337-338.
38. Rash W. Hyoid/Thyroid fracture. *J Emerg Nurs*. 2011; 37(2):182-183.
39. Sethi A, Sareen D, Chopra S, Mrig S, Agarwal AK (2005) Pharyngeal perforation with deep neck abscess secondary to isolated hyoid bone fracture. *J Laryngol Otol* 119: 1007-1009.
40. Spielmann PM, Hathorn IF, Clarke JK, Denholm S (2010) Hyoid bone fracture identified only with nasal Valsalva manoeuvre. *J Laryngol Otol* 124: 431-432.
41. Gupta R, Clarke DE, Wyer P (1995) Stress fracture of the hyoid bone caused by induced vomiting. *Ann Emerg Med* 26: 518-521.
42. Campbell AS, Butler AP, Grandas OH (2003) A case of external carotid artery pseudoaneurysm from hyoid bone fracture. *Am Surg* 69: 534-535.

**Copyright:** ©2022 Ashwin Singh Chouhan. This is an open-access article distributed under the terms of the Creative Commons Attribution License, which permits unrestricted use, distribution, and reproduction in any medium, provided the original author and source are credited.