

**Case Report**
**Open Access**

## Decompressive Craniectomy and Temporal Lobectomy in a Patient with a Traumatic Brain Injury - A Successful Case History

Dayan Dissanayaka<sup>1</sup>, Kanakka Hewage Dammika Madhusankha<sup>2\*</sup>, Dilruk Rathnayaka<sup>3</sup> and Sanath Bandara<sup>4</sup>

<sup>1</sup>Registrar Emergency medicine, National Hospital, Sri Lanka

<sup>2</sup>Registrar Emergency Medicine, National Hospital Kandy

<sup>3</sup>Registrar Emergency Medicine, National Hospital Sri Lanka

<sup>4</sup>Registrar Emergency Medicine, National Hospital Kandy, Sri Lanka

### Abstract

Traumatic brain injury is a common cause of disability among young adults. It causes a huge socioeconomic burden to the society. Management includes a multidisciplinary team approach. Both conservative and surgical options are available as a treatment option, but the outcome is often poor. Decompressive craniectomy is widely practiced surgical option for intracranial hypertension.

### \*Corresponding author

Kanakka Hewage Dammika Madhusankha, Registrar Emergency Medicine, National Hospital Kandy, Sri Lanka. Tel: 0773773103; E-mail: dammika.edu@gmail.com

**Received:** November 01, 2021; **Accepted:** November 08, 2021; **Published:** November 15, 2021

**Keywords:** Traumatic Brain Injury, Raised Intracranial Pressure, Decompressive Craniectomy, Temporal Lobectomy

### Introduction

Traumatic brain injury is a major cause of disability and death among young adults. In United Kingdom head injury is the commensals cause of death and disability in the population aged 1-40 years [1]. In Sri Lanka studies are found that most of the patients who suffer from traumatic brain injury (TBI) are working age males [2, 3]. Often outcomes of patients who suffer from traumatic brain injury are poor. An observational study done by Samanmalee S Et al found that among the patients sustaining moderate to severe TBI in Sri Lanka reveals that only 46% patients were alive after 6months of discharge and only 20% patients achieved a good recovery [4]. Another observational study done by JP Rankothkubura et al found that After craniectomy for TBI in sri lanka only 27% patients survived up to one year and only 19% achieved good outcome. These show the socioeconomic burden of TBI.

Traumatic brain injury is defined as an impact penetration or rapid movement of the brain within the skull results in altered mental state [5]. Head injury is categorized according to the initial Glasgow Coma Score (GCS). accordingly there are three categories, mild (GCS 13-15), moderate (GCS 9-12) severe (GCS 8 or less). Primary brain injury occurs at the time of the injury and it can be localized or diffuse (diffuse axonal injury). Secondary brain injury occurs from the insults after the primary impact. These includes this includes hypoxia, hypovolemia, cerebral edema and increased intracranial pressure [6].

Primary target of management of TBI is lowering the intracranial pressure medically or surgically if indicated [7]. Here we present a case of a 29 years old man who presented with a traumatic brain injury following an assault who underwent a decompressive craniectomy with temporal lobectomy and good recovery.

### Case History

29 years old previously healthy patient admitted with a sword cut injury to left parieto-temporal region and to the left wrist.

On admission to the accident and emergency department he was maintaining the airway, and the breathing was alright with normal air entry. And oxygen saturation was 100%. He was pale, tachycardic with low volume pulse rate of 150 bpm. His initial blood pressure was 80/60 and dropped to 70/50. Fluid resuscitation started with normal saline followed by uncross matched O negative blood.

His initial GCS was 13/15 and soon after admission he developed a generalized tonic clonic convulsion (GTC) and GCS dropped to 3. The convulsion was managed with intravenous midazolam, and he was intubated using the rapid sequence induction to secure the airway. His both pupils were 2mm in size reacting to the light and random blood sugar was 330 mg/dl.

He was having large deep cut wound in the left temporo-parietal region. His left hand was completely amputated from the wrist joint.

Initial Non contrast CT (NCCT) brain showed left sided compound chipping off sharp cut temporal bone fracture with underlying

fronto-temporo-parietal acute subdural hematoma (SDH) with midline shift. Towards the right-side Cerebral edema and tight brain stem also evident in the NCCT brain.

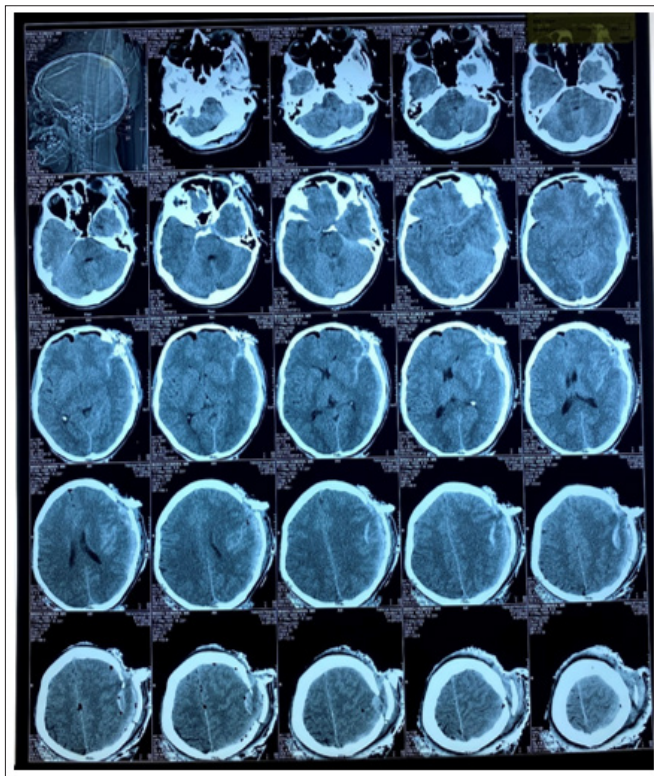


Figure 1: Initial NCCT brain

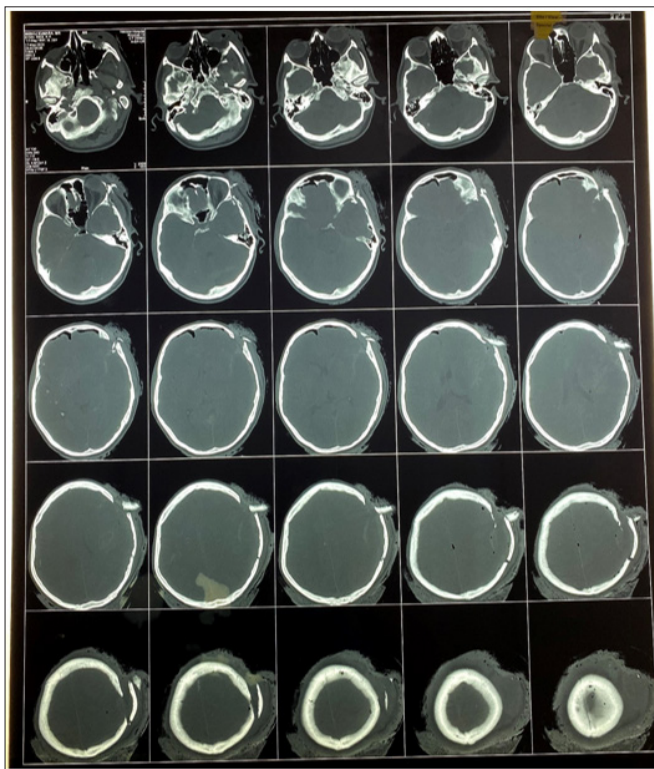


Figure 2: CT Bone Window

Emergency decompressive craniectomy planned and the patient taken to the theater after the initial haemodynamic stabilisation. Decompressive craniectomy was performed through the existing sharp cut wound and bone flap removed. After achieving the

haemostasis dura was sutured. during the same time the surgery to control the bleeding from the amputation side was performed with ligation of both ulnar and radial arteries. Patient was admitted to the ICU for further ventilatory and post-operative care. For the control of seizures patient was on phenytoin.

In the Repeat post-operative NCCT done after 12 hours and there was cerebral edema with features of increased ICP. Initially the raised ICP managed medically with 3% saline, paralysis and mechanical ventilation. Despite the medical treatment the ICP remained continuously elevated and planned to do the temporal lobectomy.

Following day patient underwent the left sided decompression and temporal lobectomy. Patient was admitted to the ICU for post operative care. Repeat CT was satisfactory and there were no features of raised ICP. patient was weaned off from the ventilator after 48 hours. Patient was extubated after 72 hours of the surgery and was having satisfactory recovery with a GCS of 14. He was having right sided weakness after the extubation. After 20 days of hospital stay patient's motor function recovered completely and was discharged from hospital.

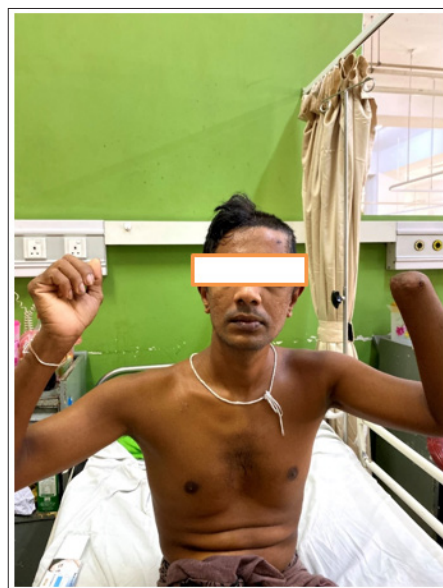

Figure 3: Patient before Discharge

### Discussion

Prevention of secondary injury is the cornerstone of the management of traumatic brain injury. This includes maintenance of cerebral perfusion pressure and application of other neuroprotective measures.

Cerebral perfusion pressure (CPP) will depend on intracranial pressure (ICP) and mean arterial pressure (MAP).

$$CPP = MAP - ICP$$

Management of ICP will play a crucial role in the treatment according to the equation. Intracranial hypertension after TBI could be due to

1. Traumatically induced masses
2. Cerebral oedema
3. Hyperaemia secondary to vasomotor paralysis
4. Hypercapnia
5. Obstruction of CSF pathways
6. Increased intrathoracic or intra-abdominal pressure [8]

There are clinical symptoms of increased ICP such as headache and vomiting. But in cases of moderate to severe TBI these symptoms are difficult to elicit as in our patient because of reduced GCS. Though the papilledema is a reliable sign it is uncommon after head injury and also difficult to assess. Among Other signs of I raised ICP includes anisocoria and decerebrate posture [8]. In the CT scan signs raised ICP includes cerebral oedema, compressed basal cisterns and midline shift. All these findings were there in our patient's initial CT scan of the brain.

Prevention or treatment of factors that may exacerbate the intracranial hypertension plays a major role in management. These includes position of the head 30 degrees elevated to allow venous drainage, paralysis and ventilation to maintain normoxia and normocarbida, and prevent seizures and fever [8]. All these conservative methods were employed in our patient.

Acute convulsions can occur because of severe TBI. These categorized as early if they occur within 7 days of the injury, or late if they occur after 7 days of injury. Phenytoin sodium is recommended to prevent early post traumatic seizures although the levetiracetam is increasingly being used [9]. In our patient phenytoin was used as he had an early post traumatic seizure. Hyperosmolar therapy usnig manitol or hypertonic saline also proven to be effctive in controlling the intracranial pressure. In some studies hypertonic saline was more effective in reducing the ICP than mannitol. Hypertonic saline has definite advantage over mannitol in hypovolemic and hypertensive patients as mannitol is relatively contraindicated in hypovolemia [8]. In our patient hypertonic saline was used to treat the intracranial hypertension.

Surgical options to treat refractory intracranial hypertension includes resection of mass lesion including evacuation of hematoma, cerebrospinal fluid drainage and decompressive craniectomy (DC) [8, 10, 11].

In our patient decompressive craniectomy was used as a modality of reducing the intracranial pressure. In brain trauma organization guidelines they doesn't give a level one recommendation on decompressive craniectomy, however recommends a large frontotemparoparietal DC over a smaller one [9]. RESCUEicp trial concluded that decompressive craniectomy in patient with TBI resulted in lower mortality rates and higher vegetative states after six months [12]. In an observational study done in national hospital of Sri Lanka found that following DC after TBI, 27% of patients survive and 19% of them had good outcome at the end of one year [2].

In our patient temporal lobectomy also done in the second opening. Evidence regarding this practice are limited, but a retrospective observational study done by Hakan AK et al found that 60% of the patient survived and all the survivors were functionally independent, but only 10 patients were included in the study. Nussbaum et al also found that 40% of the patients who underwent early decompression with complete temporal lobectomy are functionally independent [13].

In conclusion traumatic brain injury is a major cause of morbidity and mortality among young population. Management of these patient include a multidisciplinary approach including emergency physicians, aneashtetists, neurosurgeons and intensivists. Prevention of secondary injury to the brain by preventing the intracranial hypertension is the cornerstone of the management. To achieve this goal both medical and surgical interventions needed

simultaneously in severe or refractory cases.

## References

1. Introduction | Head injury: assessment and early management | Guidance | NICE [Internet]. NICE; [cited 2020 Oct 25]. Available from: <https://www.nice.org.uk/guidance/cg176/chapter/Introduction>
2. Rankothkumbura J, Guanathilake Y, Thoradeniya T, Shiyam A, Wadanamby S (2018) Outcomes of Decompressive Craniectomy for Traumatic Brain Injury at a Major Trauma Centre in Sri Lanka.
3. Weerasinghe N, Athiththan S, Wadanamby S (2015) An audit on patients with head injury who were admitted to neurotrauma unit National Hospital Sri Lanka. *Anuradhapura Med J* 9: S12.
4. S Samanmalee, PC Sigera, AP De Sillva, K Thilakasiri, A Rashan, et al. (2018) Traumatic brain injury (TBI) outcomes in an LMIC tertiary care centre and performance of trauma scores [Internet]. Vol. 18, *BMC anesthesiology*. *BMC Anesthesiol*; 2018 [cited 2020 Oct 26]. Available from: <https://pubmed.ncbi.nlm.nih.gov/29310574/>.
5. Prins M, Greco T, Alexander D, Giza CC (2013) The pathophysiology of traumatic brain injury at a glance. *Dis Model Mech* 6:1307.
6. Morten CC, Michael Gilhooly, RK (2020) Classifying Types of Brain Injury. 2020 Oct 19 [cited 2020 Oct 26]; Available from: <https://www.bmj.com/rapid-response/2011/11/02/classifying-types-brain-injury>
7. Hakan A, Daltaban IS, Vural S (2019) The Role of Temporal Lobectomy as a Part of Surgical Resuscitation in Patients with Severe Traumatic Brain Injury. *Asian J Neurosurg* 14: 436-439.
8. Rangel-Castillo L, Gopinath S, Robertson CS (2008) Management of Intracranial Hypertension. *Neurol Clin* 26: 521-541.
9. Carney N, Totten AM, O'Reilly C, Ullman JS, Hawryluk GWJ, Bell MJ, et al. Guidelines for the Management of Severe Traumatic Brain Injury 80: 6-15.
10. Dashnaw ML, Petraglia AL, Huang JH (2020) Surgical Treatment of Severe Traumatic Brain Injury. *Trauma Brain Inj* [Internet]. 2014 Feb 19 [cited 2020 Oct 28]; Available from: <https://www.intechopen.com/books/traumatic-brain-injury/surgical-treatment-of-severe-traumatic-brain-injury>
11. [Guidelines\\_for\\_the\\_Surgical\\_Management\\_of\\_TBI.pdf](#) [Internet]. [cited 2020 Oct 28]. Available from: [https://www.braintrauma.org/uploads/01/13/Guidelines\\_for\\_the\\_Surgical\\_Management\\_of\\_TBI.pdf](https://www.braintrauma.org/uploads/01/13/Guidelines_for_the_Surgical_Management_of_TBI.pdf)
12. Hutchinson PJ, Koliass AG, Timofeev IS, Corteen EA, Czosnyka M, et al (2016) Trial of Decompressive Craniectomy for Traumatic Intracranial Hypertension. *N Engl J Med* 375: 1119-1130.
13. Nussbaum ES, Wolf AL, Sebring L, Mirvis S (1991) Complete temporal lobectomy for surgical resuscitation of patients with transtentorial herniation secondary to unilateral hemispheric swelling. *Neurosurgery* 29: 62-66.

**Copyright:** ©2021 Kanakka Hewage Dammika Madhusankha, et al. This is an open-access article distributed under the terms of the Creative Commons Attribution License, which permits unrestricted use, distribution, and reproduction in any medium, provided the original author and source are credited.